



If CAD is caught early by MCG (Multi-function Cardiography) test, ACS can be highly preventable in Myanmar by Doing MCG Test.

Than Htay, Thet Hein, Myint Zaw, Pyay Nyein Mg, Ag Ag, Wai Phyo, Nway Nay Chi Naing, Myint Zu Thin, Kinzo Ueda

Japan Myanmar Medical Help Group (JMMHG) Activity

Disclosure: There are no financial or other relationships that might lead to a conflict of interest.

Background

Among the deaths by non-communicable diseases, Coronary artery disease (CAD) is the highest cause of death in Myanmar. Because the number of heart centers with Cath Lab is limited in Myanmar, accurate diagnosis of CAD patient is more important to start appropriate (PCI/Optimal Medical Therapy) treatment.

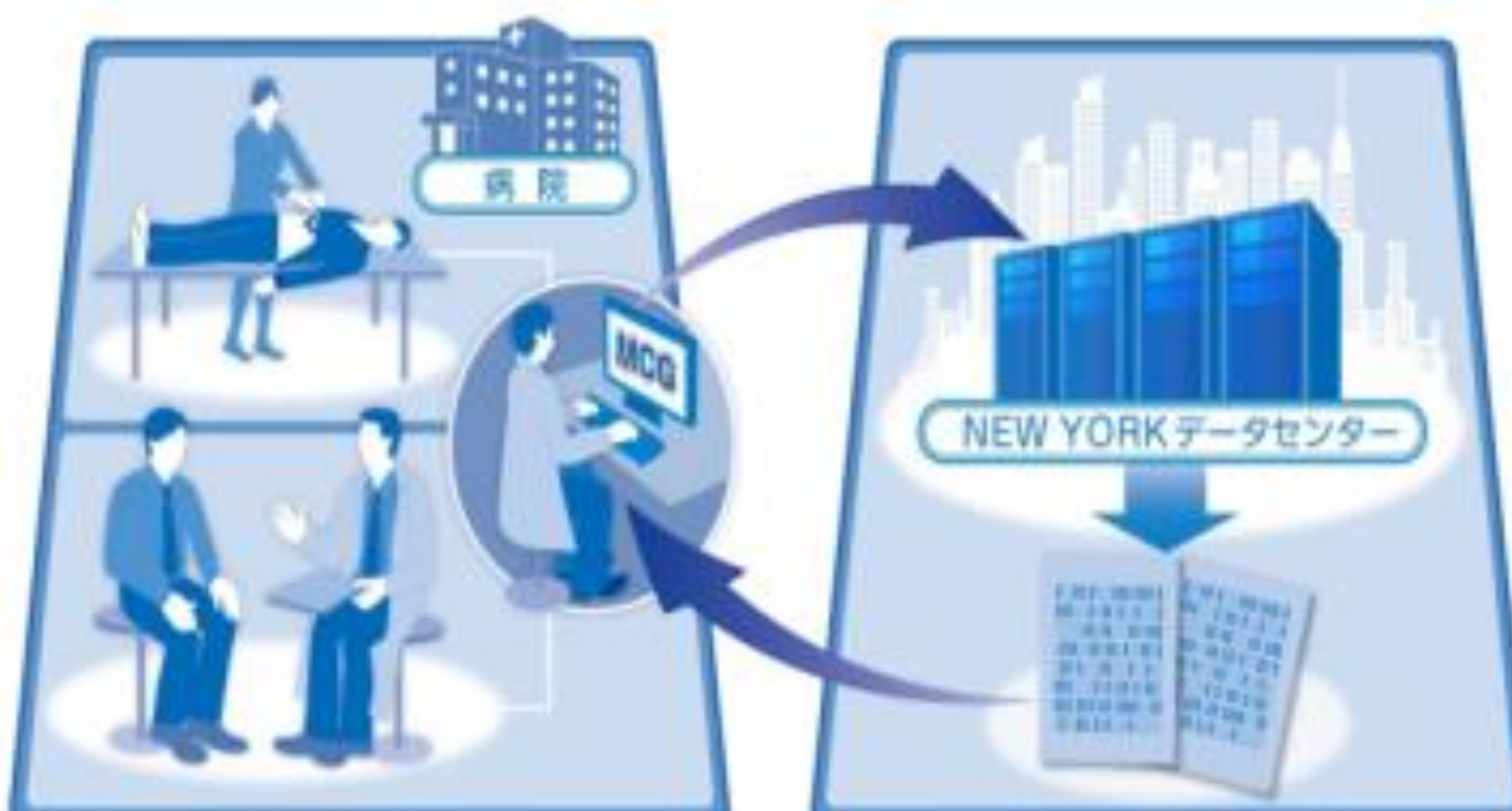Purpose

MCG is the non-invasive new technology developed to detect IHD by analyzing the resting ECG. This study is to evaluate whether MCG can be feasible for early detection of CAD in patients with or without chest pain by comparing with CAG to start appropriate treatment in order to prevent ACS.

Method

Total 20 patients (Average age 59 ± 7.1 , Male:17, Female:3) with MCG (≥ 4 score) scheduled to do CAG were selected. Coronary Stenosis of $\geq 75\%$ (75%~100% of stenosis) in a single or multiple vessels is defined as severe CAD necessary to start an appropriate treatment.

MCG score ≥ 6 , 5, 4 were used as cut-off respectively to indicate presence of coronary stenosis ($\geq 75\%$).



MCG Results		ischemia Results	
ID	testing date	ECG Tracking Quality	Result
05188981	2015-02-04 17:32	good	Present
05188982	2015-02-04 17:32	good	Absent
05188983	2015-02-04 17:32	good	Absent
05188984	2015-02-04 17:32	marginal	Absent
05188985	2015-02-04 17:32	marginal	Present

Result

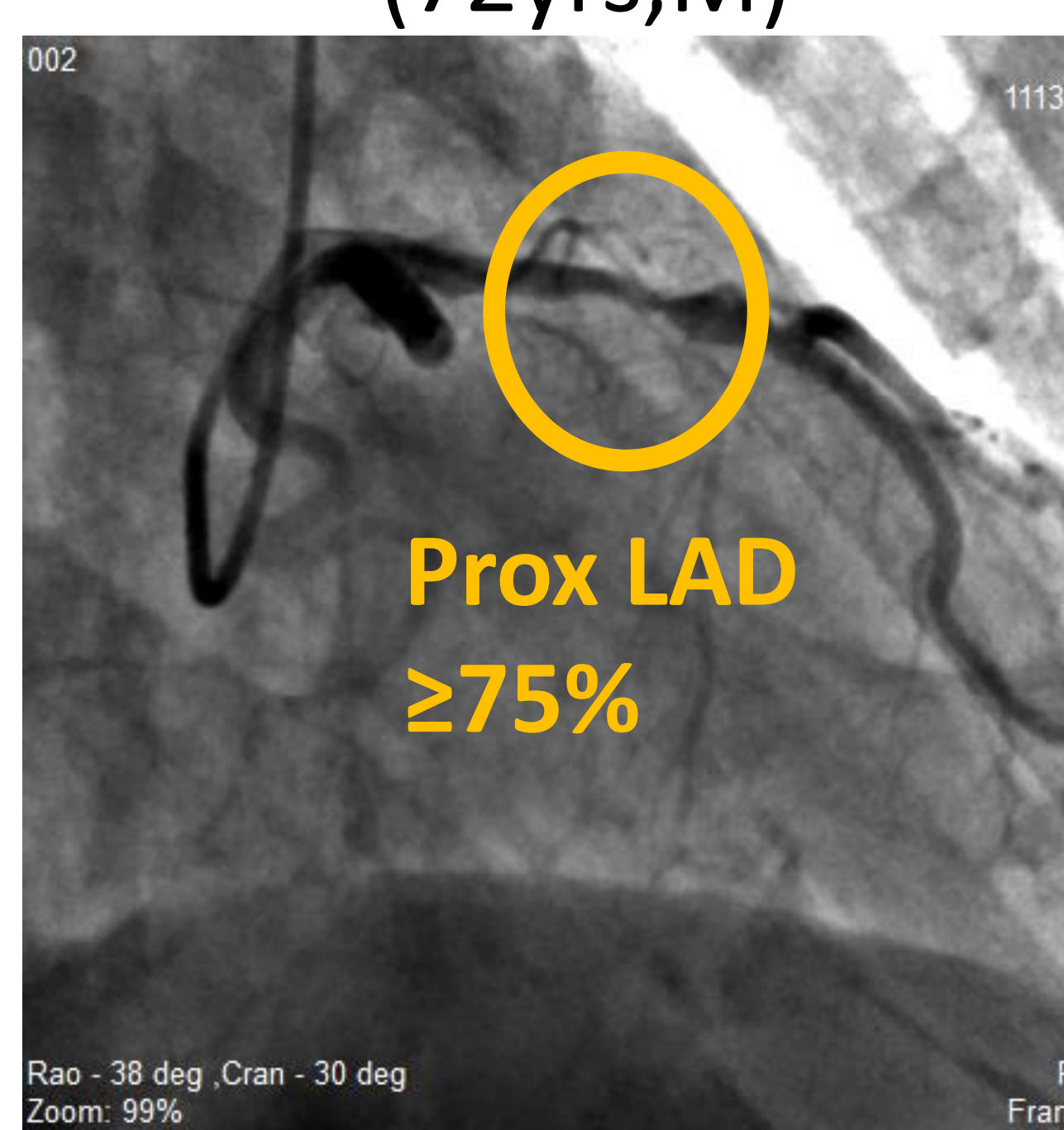
MCG scores in patients with or without severe CAD are significantly different. (with CAD: 6.5, without CAD:4.9, $p < 0.001$). Best cut off value is MCG score ≥ 6 , and is identified sensitivity 80.0%, specificity 90.0%, PPV 88.9%, NPV 81.8%, and accuracy 85.0% ($p < 0.01$). Score 6.0 is categorized as high in MCG session analysis.

<Table2> Results of CAG findings and MCG analysis

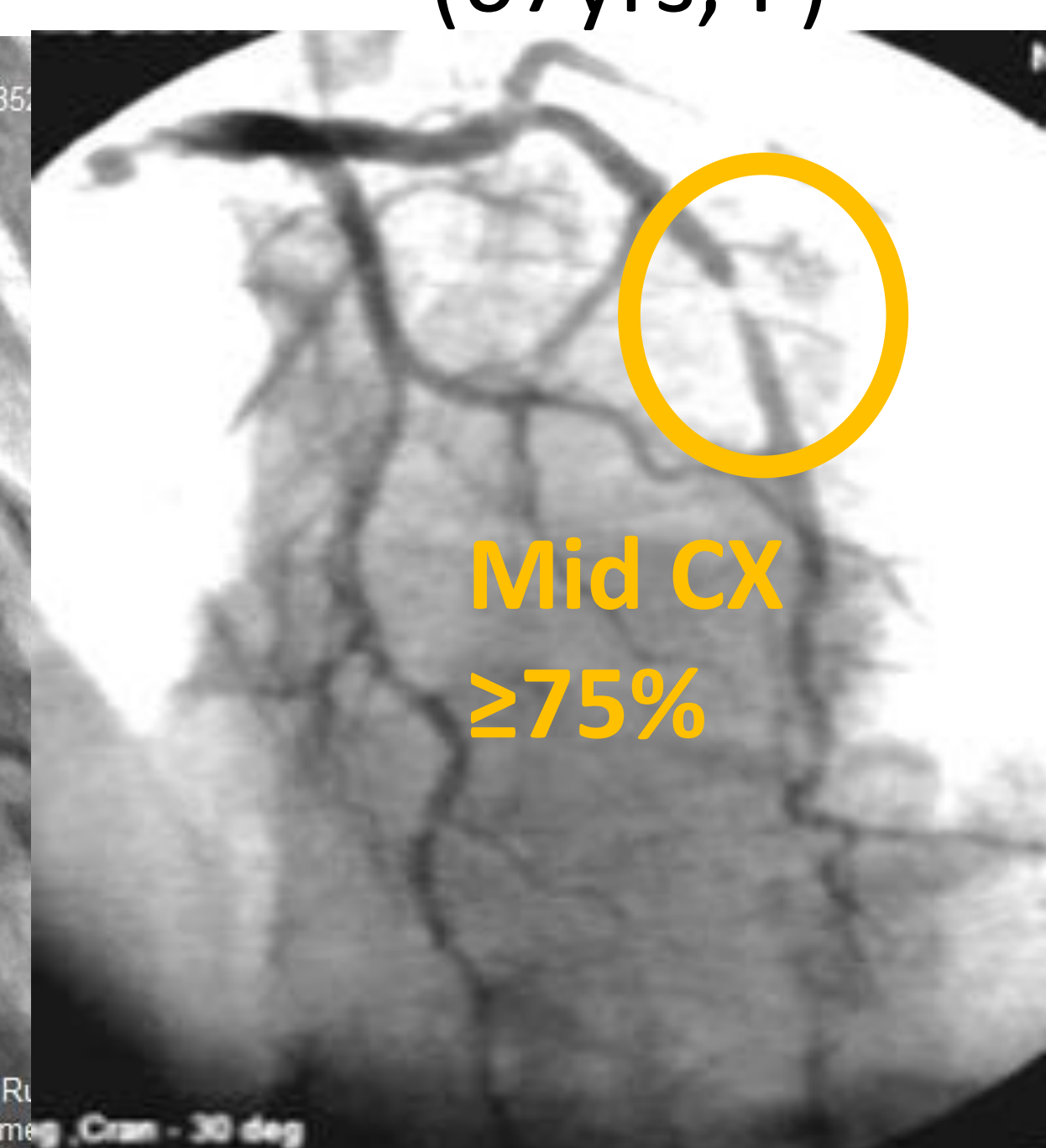
	CAD(+)	CAD(-)	Best cut off value: 6.0 Sensitivity 80.0% , Specificity 90.0%, PPV 88.9%, NPV 81.8%, Accuracy 85.0%.
MCG(+)	8	1	
MCG(-)	2	9	

($P < 0.01$)

<Figure2-①>
(72yrs, M)



<Figure2-②>
(67yrs, F)



(CAG)

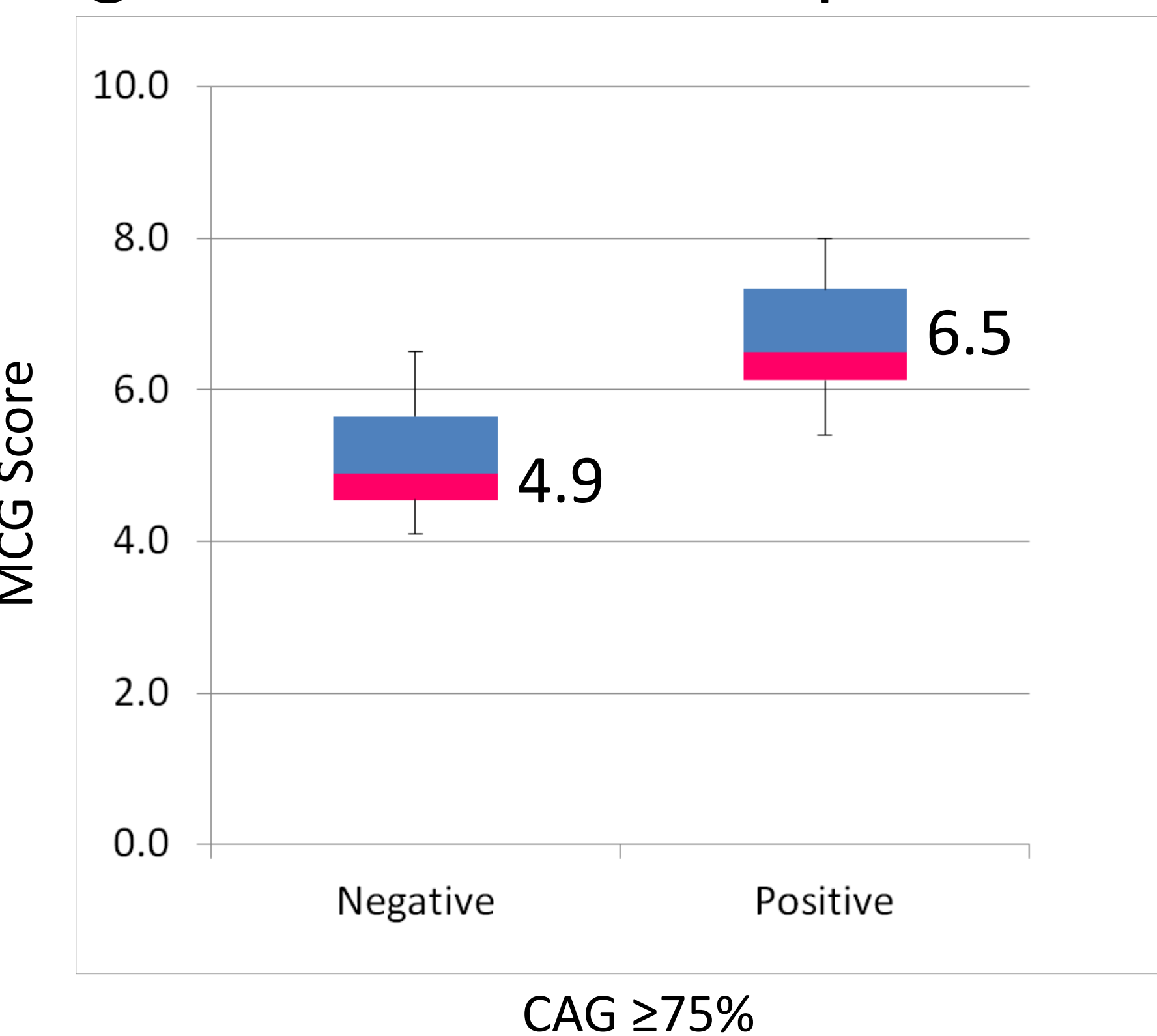
(CAG)

MCG	Score	MCG	Score
test1	7	test1	5.5
test2	5.5	test2	5.5
test3	6	test3	8
test4	7	test4	5.5
test5	7	test5	6
Average	6.5	Average	6.1

(MCG)

(MCG)

<Figure1> MCG score in patients with or without CAD



MCG scores in patients with or without severe CAD are significantly different. ($P < 0.001$)

Conclusion

MCG showed high sensitivity and specificity, and high score of MCG likely indicates the presence of severe CAD. MCG can be used for early detection and follow-up of CAD, same as diagnosed by CAG in order to start the appropriate necessary (PCI/Optimal Medical Therapy) treatment before the occurrence of ACS.

Discussion

There were 2 patients with MCG score < 6 (false negative) noted severe CAD with collateral flow in CAG. There was 1 patient with MCG score ≥ 6 (false positive) noted normal CAD in CAG, it may be due to vasospasm. The patients without severe CAD group have also $< 50\%$ or $< 75\%$ stenosis expect one normal patient. It suggests that MCG score may indicate an early stage of arteriosclerosis in that patient.

The usefulness of MCG at early stage of arteriosclerosis will be evaluated in the future study.

JMMHG aims to reduce the incidence rate of ACS in urban and rural population. Collaboration and cooperation of all Japan/Myanmar stakeholders (If possible), partners like academia, civil societies and community/companies are obviously necessary for the successful implementation for early diagnosis of CAD by MCG test because total 15 Cath Labs and not more than 50 interventional cardiologists can not cover the whole area of Myanmar to detect the early diagnosis of CAD to be able to start the appropriate necessary (PCI/Optimal Medical Therapy) treatment before the occurrence of the ACS in Myanmar.